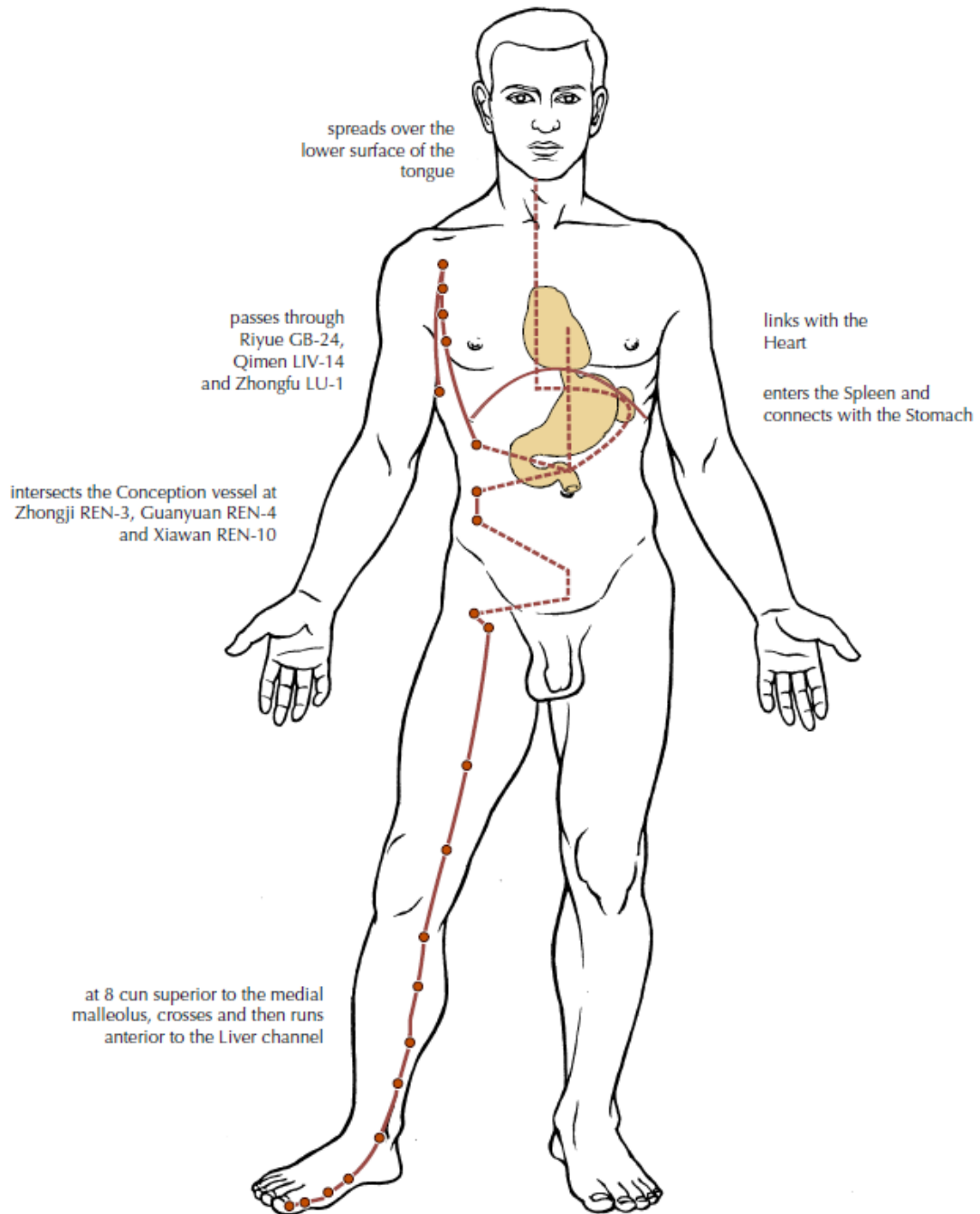
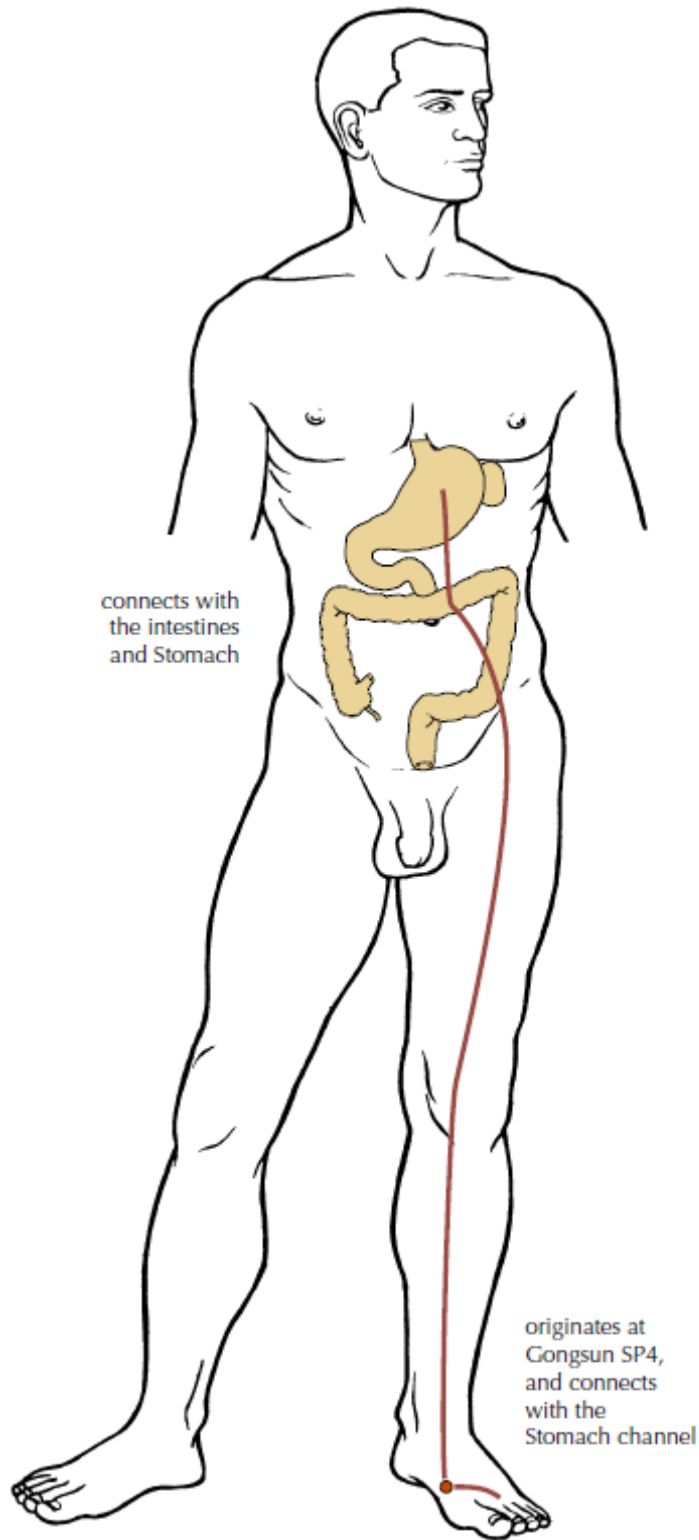
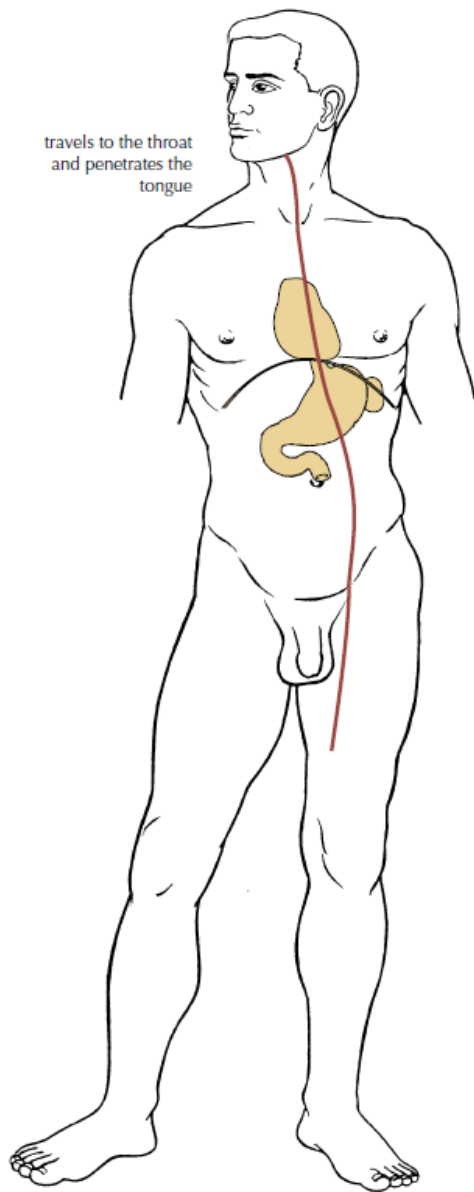


THE SPLEEN CHANNEL OF FOOT TAIYIN

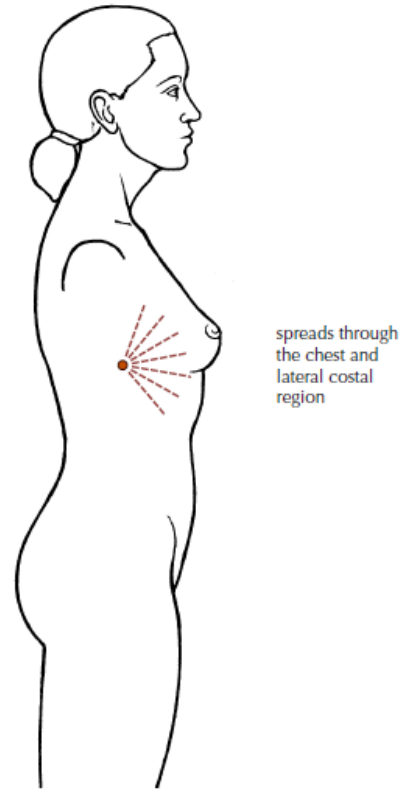




The Luo-connecting channel of the Spleen



The divergent channel of the Spleen



The great luo-connecting channel of the Spleen

SPLEEN

| FOOT | DEADMAN | CAM |
|-----------------|---|---|
| Spleen 1 | On the dorsal aspect of the big toe at the junction of lines drawn along the medial border of the nail and the base of the nail, approximately 0.1 cun from the corner of the nail. | <i>On the medial side of the great toe, about 0.1 cun posterior to the corner of the nail.</i> |
| Spleen 2 | On the medial side of the big toe, in the depression distal and inferior to the first metatarso-phalangeal joint. | <i>On the medial side of the great toe, distal and inferior to the first metatarsodigital joint, in the depression of the junction of the red and white skin.</i> |
| Spleen 3 | On the medial side of the foot in the depression proximal and inferior to the head of the first metatarsal bone. | <i>Proximal and inferior to the 1st metatarsophalangeal joint, in the depression of the junction of the red and white skin.</i> |
| Spleen 4 | On the medial side of the foot, in the depression distal and inferior to the base of the first metatarsal bone. | <i>In the depression distal and inferior to the base of the first metatarsal bone, at the junction of the red and white skin.</i> |

ANKLE

| | | |
|-----------------|--|--|
| Spleen 5 | On the medial side of the ankle, in the depression which lies at the junction of straight lines drawn along the anterior and inferior borders of the medial malleolus. | <i>In the depression distal and inferior to the medial malleolus, midway between the tuberosity of the navicular bone and the tip of the medial malleolus.</i> |
|-----------------|--|--|

LOWER LEG

| | | |
|-----------------|--|--|
| Spleen 6 | On the medial side of the lower leg, 3 cun superior to the prominence of the medial malleolus, in a depression close to the medial crest of the tibia. | <i>3 cun directly above the tip of the medial malleolus, posterior to the medial border of the tibia.</i> |
| Spleen 7 | On the medial side of the lower leg, 3 cun superior to SP-6, in a depression just posterior to the medial crest of the tibia | <i>6 cun from the tip of the medial malleolus, on the line connecting the tip of the medial malleolus and SP 9, posterior to the medial border of the tibia.</i> |

| | DEADMAN | CAM |
|-----------------|--|---|
| Spleen 8 | On the medial side of the lower leg, 3 cun inferior to SP-9, in a depression just posterior to the medial crest of the tibia | <i>3 cun below SP 9, on the line connecting SP 9 and the medial malleolus.</i> |
| Spleen 9 | On the medial side of the lower leg, in a depression in the angle formed by the medial condyle of the tibia and the posterior border of the tibia. | <i>On the lower border of the medial condyle of the tibia, in the depression posterior and inferior to the medial condyle of the tibia.</i> |

UPPER LEG

| | | |
|------------------|---|---|
| Spleen 10 | 2 cun proximal to the superior border of the patella, in the tender depression on the bulge of the vastus medialis muscle, directly above SP-9. | <i>When the knee is flexed, the point is 2 cun above the mediosuperior border of the patella, on the bulge of the medial portion of m. quadriceps femoris.</i> |
| Spleen 11 | On the medial side of the thigh, 6 cun superior to SP-10, on a line connecting SP-10 with SP-12. | <i>6 cun above SP 10, on the line drawn from SP 10 to SP 12.</i> |
| Spleen 12 | 3.5 cun lateral to REN-2, on the lateral side of the femoral artery. | <i>Superior to the lateral end of the inguinal groove, lateral to the pulsating external iliac artery, at the level of the upper border of symphysis pubis, 3.5 cun lateral to Ren 2.</i> |

ABDOMEN

| | | |
|------------------|---|---|
| Spleen 13 | On the lower abdomen, 0.7 cun superior and 0.5 cun lateral to SP-12, 4 cun lateral to the midline. This point is also defined as lying 4.3 cun inferior to SP-15. | <i>4 cun below the centre of the umbilicus, 0.7 cun superior to SP 12, 4 cun lateral to the anterior midline.</i> |
| Spleen 14 | On the lower abdomen, 1.3 cun inferior to SP-15, 4 cun lateral to the midline. | <i>1.3 cun below SP 15, 4 cun lateral to the anterior midline, on the lateral side of m. rectus abdominis.</i> |
| Spleen 15 | On the abdomen, in the depression at the lateral border of the rectus abdominis muscle level with the umbilicus. | <i>4 cun lateral to the center of the umbilicus, lateral to m. rectus abdominis.</i> |
| Spleen 16 | On the abdomen, in depression at the lateral border of the rectus abdominis muscle, 3 cun superior to SP 15. (In some patients, may fall on the costal margin.) | <i>3 cun above the centre of the umbilicus, and 4 cun lateral to the anterior midline.</i> |

| CHEST | DEADMAN | <i>CAM</i> |
|------------------|--|--|
| Spleen 17 | On the lateral side of the chest, in the fifth intercostal space, 6 cun lateral to the midline. | <i>In the fifth intercostal space, 6 cun lateral to the midline.</i> |
| Spleen 18 | On the lateral side of the chest, in the fourth intercostal space, 6 cun lateral to the midline. | <i>In the fourth intercostal space, 6 cun lateral to the anterior midline.</i> |
| Spleen 19 | On the lateral side of the chest, in the third intercostal space, 6 cun lateral to the midline. | <i>In the third intercostal space, 6 cun lateral to the anterior midline.</i> |
| Spleen 20 | On the lateral side of the chest, in the second intercostal space, 6 cun lateral to the midline. | <i>In the second intercostal space, 6 cun lateral to the anterior midline.</i> |
| Spleen 21 | On the mid-axillary line, in the seventh intercostal space. (some sources say sixth) | <i>On the lateral side of the chest and on the middle axillary line, in the sixth intercostal space.</i> |